

Adult female sea lion with advanced throat swelling.



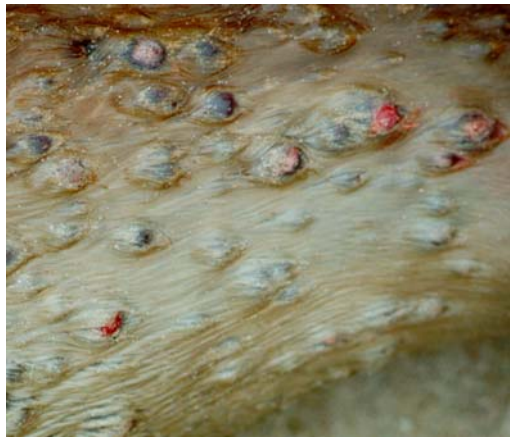
Adult female sea lion with thoracic and abdominal lesions.



Dead adult female sea lion with dorsal and lumbar lesions.



Dead adult female sea lion with extensive ventral lesions.



Detail of lesions on abdomen of adult female sea lion.

Dead sea lion pups were accumulated in several localities during the mortality event to prevent multiple counting and the spread of disease.



An ill wind: a sea lion carcass is scavenged by a brown skua.

*All photos by Simon Childerhouse, Nadine Gibbs, and Nick Gales.*